

# PERSISTENT CLOACA - A CHALLENGE FOR AN EXPERIENCED SONOGRAPHER



**Authors:**

Marek Blitek<sup>1</sup>, Maciej Stodki<sup>2,3</sup>, Hanna Moczulska<sup>2,4</sup>, Anna Piaseczna-Piotrowska<sup>5</sup>, Maria Respondek-Liberska<sup>2,6</sup>

1. Subdivision of High Risk Pregnancy, State Hospital in Zielona Góra 2. Department of Prenatal Cardiology, Polish Mother's Memorial Hospital Research Institute 3. Institute of Health Sciences, The State School of Higher Professional Education in Plock 4. Department of Genetics, Polish Mother's Memorial Hospital Research Institute 5. Department of Children Surgery, Polish Mother's Memorial Hospital Research Institute 6. Department of Diagnoses and Prevention Fetal Malformations Medical University of Lodz

PRENAT CARDIO. 2014 MAR;4(1):17-22  
DOI 10.12847/03144

**Abstract**

This was a retrospective analysis of ultrasonographic and echocardiographic examinations in 12 fetuses with postnatally confirmed Cloacal Malformation. All examinations were conducted at the tertiary fetal diagnostic center (none of the preliminary screening diagnoses were correct). The main manifestations of cloacal malformation were: signs of urinary tract malformations in 10 fetuses (83,33%), pelvic cyst, diagnosed or suspected as hydrocolpos in 9 fetuses (75%), signs of lower part of digestive tract obstruction in 6 fetuses (50%). In addition there were abnormalities in echocardiographic examinations in 6 cases, such as symptoms of cardiac failure (cardiomegaly, tricuspid regurgitation, monophasic inflow, pericardial effusion, ascites) and one case with AS ( aortal stenosis). Functional abnormalities in fetal echocardiography suggest increased preload or afterload and early circulation failure in this severe prenatal malformation. This malformation have never been published before. The data suggest, that fetal functional echocardiography abnormalities in cases of abnormal pelvic structures should alert the clican to possibility of the presence of cloaca..

**Key words:** persistent cloaca, cloacal malformation, pelvic cyst, hydrocolpos, hydrometrocolpos, obturative uropathy, anal athresia, fetal echocardiography.

**BACKGROUND**

Persistent Cloaca, Cloacal Malformation, is a complex urogenital defect, manifested by a wide spectrum of clinical and ultrasound images. Prenatal diagnosis of defects of the anus is estimated between 0- 5,9%. Difficulties in the prenatal diagnosis of this complex defects rely on the relatively rare occurrence, the lack of proper understanding the pathophysiology of this defect and, hence lack of knowledge about characteristic sonographic findings. In Polish literature there is no original publication of the prenatal diagnosis of Cloacal Malformation, in Polish-language literature works on the subject are few. Therefore, we decided to explore our own material at a reference tertiary fetal diagnostic center.

**MATERIAL AND METHODS**

We analyzed retrospectively the results of 17 studies in which sonography and echocardiography were conducted in the referral center for fetal abnormalities

in 12 fetuses, with were confirmed after completion of pregnancy to be Cloacal Malformations. The analysis reports, frozen images and videos were recorded at our institution. With the following parameters: the year of the evaluation, maternal age, type of pregnancy (low or high risk), fetal weight, fetal age, initial diagnosis, suspected or diagnosis of Cloacal Malformation.(Table1 ).

The material was analyzed for the presence of the following abnormalities (Table 2.):

Symptom of pelvic cyst / hydrocolpos / hydrometrocolpos - fetal pelvic cyst.

Obstructive uropathy symptoms or other symptoms of urinary tract defects

Obstruction of the lower gastrointestinal tract.

Symptoms associated with any cardiovascular pathology

Other anomalies.

Echocardiography was analyzed for the occurrence

**How to Cite this Article:**

Blitek M, Stodki M, Moczulska H, Piaseczna-Piotrowska A, Respondek-Liberska M.

Persistent cloaca - a challenge for an experienced sonographer  
Prenat Cardio. 2014 Mar;4(1):17-22

Corresponding author: marekblitek@gmail.com

Submitted: 2014-03-18; accepted: 2014-04-16

Lp.	Year of examination	Maternal age (years)	High risk pregnancy	Low risk pregnancy	Fetal estimated weight (g)	Gestational age (in weeks)	Screening US and preliminary diagnoses	Diagnoses of cloaca in our referral center
1. KI	1994	21	1		3324	38	Abdominal cyst	Yes
2. SA	2006	29	1			15	Omphalocele	Yes
3. KK	2007	17	1		1889	28	Omphalocele	Yes
4. ZM	2008	29	1		1890	33	Uropathy	Yes
5. RB	2009	36		1		28	Ascites	Yes
6. WM	2009	32		1	641	23	Hydronephrosis	Yes
7. GL	2009	31		1	620	24	Megacystis	Yes
8. KJ	2010	26	1		2223	37	Gastroschisis	Yes
9. AM	2011	19	1		165	18	Megablader	Yes
10. KT	2012	31	1		955	26	Megablader	Yes
11. SL	2012	33	1		954	27	Oligohydramnion	No (exam after shunt insertion)
12. RK	2012	26	1		1953	31	Ascites, renal cyst	Yes
:		Average 27,5	9 x	3x	Average 1328,55 g	Average 27,33	Proper diagnosis after screening 0 (none)	11 (91,17%)

Table 1: Analysis of anomalies in 12 fetuses with cloaca

of invalid heart size, abnormal images of four chambers view, impaired mediastinal image at the level three vessels view, impaired view of ventricular outlet tracts, as well as for functional abnormalities.

**RESULTS**

Specific anomalies in the years 1994- 2012 were recorded –we found that there were

1-2 cases per year. The average maternal age was 27.5 years (from d 17 to 36 years). In 9 cases there was a low-risk pregnancies, and 3 cases of high-risk pregnancies. The risk factors were: maternal age, poor obstetric history and gestational diabetes. The average weight of fetuses examined was 1328,55, ( 165 g – 2223 g). The fetuses were diagnosed between 15 and 38 weeks of pregnancy.

All preliminary

diagnoses based on screening ultrasound were incorrect. The correct diagnosis in our referral center was made in 11 out of 12 cases. A single case of misinterpretation of the changes concerned the fetus after intrauterine therapy with the assumption that the shunt was due to a cystic tumor diagnosed as obstructive uropathy. (Table 1 ). After a retrospective analysis of images and videos of registered studies, we found that the most frequent features were: uropathies in 10/12 fetuses (83,3 %), cystic changes in the pelvis 9/12 (75%). In 50% of fetuses symptoms suggestive of anomalies of the distal part of the gastrointestinal tract were present and also in 50% was observed abnormalities on echocardiography (Table 2 ).

Results of the analysis showed that echocardiography in 3 fetuses (of 12 ) had cardiomegaly (HA / CA> 0.45), there were observed in 2 fetuses disproportion in the picture 4 heart chambers, only in one case was a structural heart

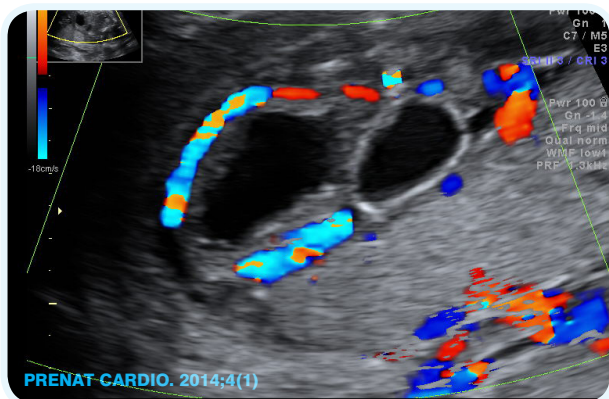


Photo1. Abnormal fetal lower abdomen suggested “tripart bladder” - cloaca

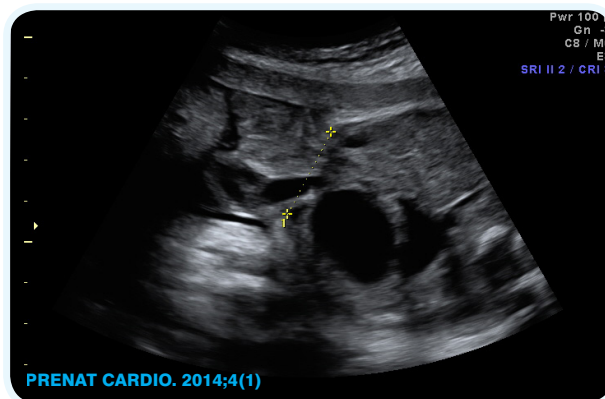


Photo 2. Fetal gastroschisis (proper screening diagnosis), however missed diagnosis of “abnormal two parts of fetal bladder (cloaca)

Lp.	Pelvic cyst	Uropathy	Digestive tract abnormalities	Anomalies in the fetal heart	Other
1.	Yes	No	No	No	No
2.	Yes	Yes	Yes	No	No
3.	Yes	No	No	No	No
4.	Yes	Yes	Yes	No	No
5.	Yes	Yes	Yes	Yes	No
6.	Yes	Yes	No	No	No
7.	Yes	Yes	No	Yes	Yes,SUA
8.	No	Yes	Yes	Yes	Yes gastroschisis
9.	No	Yes	Yes	Yes	Hypoterolism
10.	Yes	Yes	Yes	No	No
11.	No	Yes	No	Yes	No
12.	Yes	Yes	No	Yes	Hepatomegaly
TOTAL:	9 (75%)	10 (83,33%)	6 ( 50%)	6 (50%)	4 (33,33%)

Table 2 Analysis of anomalies in 12 fetuses with persisten cloaca in US and ECHO

defect in the form of aortic stenosis present. In assessing the state of cardiovascular fitness by CVPS half of the respondents fetuses were healthy, but in another half of cases there was recorded various functional changes resulting in a reduction of 7-9 CVPS. These changes were: pericardial effusion, cardiac hypertrophy, abnormal cardiac axis, tricuspid regurgitation, monophasic flow through the tricuspid valve (Table 3 ).

**DISCUSSION OF THE RESULTS:**

It is estimated that Cloacal Malformation occur with an incidence of : 50 000 live births<sup>1</sup> . Hendren gives the incidence of defects as on in 250 000 births, and this fact can be explained by poor knowledge of the occurrence of this anomaly in sonographers performing screening examination of fetuses in both Poland (Table 1 ) and the United States. The essence of the anatomy of the defect is persistent early embryological stage, in which there is a common outlet of the urinary tract, vagina and gastrointestinal tract. The urethra, vagina and

rectum remain connected in the pelvis to form a common channel of variable length, the UGS - Urogenital sinus, which opens in the place of the typical urethral meatus. Another element of the complex is likely related to a valvular mechanism that causes the accumulation of urine, liquid, and meconium within the vagina, forming a cystic structure called a hydrocolpos.

Accompanied by this defect occur often (40%) persistent dual Mullerian system with the presence of a double uterus and double vagina. In the double uterus or double uterine cavities (uterus dydelphis) may be visible liquid together hydrometrocolpos image. Additionally, it may be unilateral agenesis Mullerian structures with unilateral occurrence hydrometrocolpos image. Additional urinary tract defects are most likely related to the mechanism of compression by the hydrocolpos compressing the surrounding area of the bladder triangle, to lead to bladder symptoms of obstructive uropathy with varying degrees of severity. In a similar mechanism the loop of the bowel can be widened.

According to the literature the typical discovery in prenatal diagnostics are cystic changes in the pelvis and abdomen of the fetus, which is a combination of an image hydrometrocolpos, obstructive uropathy and widened loop of bowels. These data confirm our observations (table 2). According to Bischoff<sup>2</sup> the main symptom: pelvic cyst - hydrocolpos, hydrometrocolpos - occurs in about 52 % of cases, in our material it occurred in 9 fetuses (75%). Pelvic cyst caused by hydrocolpos is localized behind the bladder, central in the middle of the pelvis. Echogenicity may be reduced, may be visible characteristic of the image related to the presence or uterine dydelphis. The uterine cavity may be filled with fluid. This gives for the uterus dydelphis image “rabbit ears”. This symptom may be mistakenly interpreted as a diverticulum of the bladder. Differentiation of an enlarged hydrocolpos and the bladder is based on the center position of hydrocolpos and on

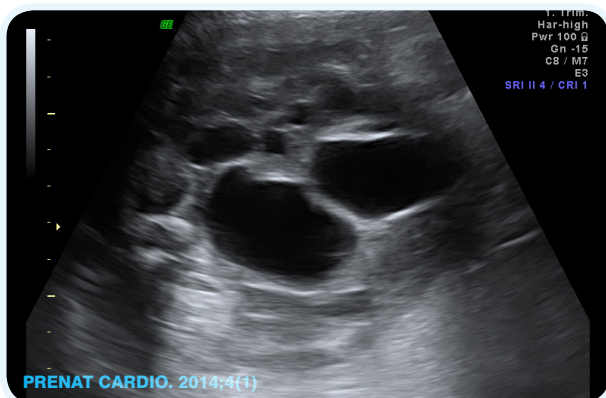


Photo 3. Abdominal cysts suggested uropathy in case of fetal cloaca

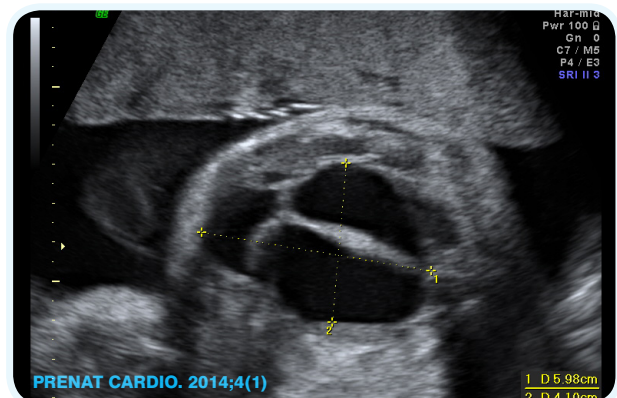


Photo 4. Abnormal fetal pelvic (in female) suggesting hydrometrocolpos

Lp.	HA/CA	4CHV	LVOT, RVOT	CVPS	INNE
1.	0,3	NORMAL	NORMAL	10	NO
2.	0,3	NORMAL	NORMAL	10	NO
3.	0,36	NORMAL	NORMAL	10	NO
4.	0,4	NORMAL	NORMAL	9	NO
5.	0,45	NORMAL	CHD:AS	7	Hydrops Cardiomegaly Hypertrophy Pericardial effusion
6.	0,33	NORMAL	NORMAL	10	NO
7.	0,32	NORMAL	NORMAL	10	SUA, vena azygos Pericardial effusion
8.	0,36	Disproportion	NORMAL	8	Pericardial effusion
9.	0,46	NORMAL	NORMAL	9	Heart axis 90
10.	0,34	NORMAL	NORMAL	10	NO
11.	0,42	NORMAL	NORMAL	7	Cardiomegaly Ascites, SF RV 24%
12.	0,49	Disproportion	NORMAL	8	Cardiomegaly, TR, TV monophasic flow
TOTAL: 6 (50%)	HA/CA >0,45 3 plody	2 (16,67%)	1 (8,33%)	6	7 (50%)

Table 3: Fetal echocardiographic data in 12 fetuses with cloaca

attempting to find the compressed bladder forward of the mass. The main symptom needs the use of color Doppler and defined a course in the bladder wall the arteries extending from the upper bladder iliac vessels to the umbilical ring. Cloacal Malformation can coexist with a single umbilical artery (SUA), and thus the bladder wall may be shown with only one vessel. Diagnosis is easier in the case of the presence of two cystic masses in midline of which first is the image of the central hydrocolpos and towards the front – a filled bladder. Within hydrocolpos sedimentation can be seen which is meconium content associated with the mass. Differentiation the hydrokolpos and an ovarian cysts is based on lateral position of ovaria and ovarian cysts typically located behind the broad ligament, and so more forward the rear of the pelvis. In isolated ovarian cysts there are also signs of obstructive uropathy, which is part of the persistent cloaca. Currently, in case of suspicion of hydrocolpos MRI of the fetus (in our case series such examination is not performed)

can be performed. Differentiation of mass in type hydrocolpos in the course of persistent cloaca and hydrocolpos in the course of atresia of the hymen, or a defect in the Urogenital Sinus, so in fetuses with properly developed anus, is to raise the profile of meconium in the rectum .

Fetuses with congenital Cloacal Malformation showed images associated with obstructive uropathy : hydronephrosis (49%), oligohydramnios ( 26%), megaurether, enlarged bladder, multicystic dysplastic kidney, absence of kidney , often horseshoe kidney. In our study, 10 fetuses (83,33%) presented symptoms uropathies.

Images associated with the compression of “tumor mass” on the intestine known from the literature such as: Dilated colon (18 %), echogenic bowel, calcification of the large bowel. in our material presented 6 fetuses (50%).

Images related to additional malformations of the gastrointestinal tract: polyhydramnios, duodenal atresia symptoms, esophageal atresia, diaphragmatic hernia , in our material did not occur. In the literature and in our study appeared echogenic bowel contents within the fetal bladder which probably is related to the mixing of urine with meconium . In the literature attention is noted of the frequent co-occurrence of esophageal atresia and duodenal atresia, diaphragmatic hernia, spinal defects and congenital heart defects (Tetralogy of Fallot in particular),

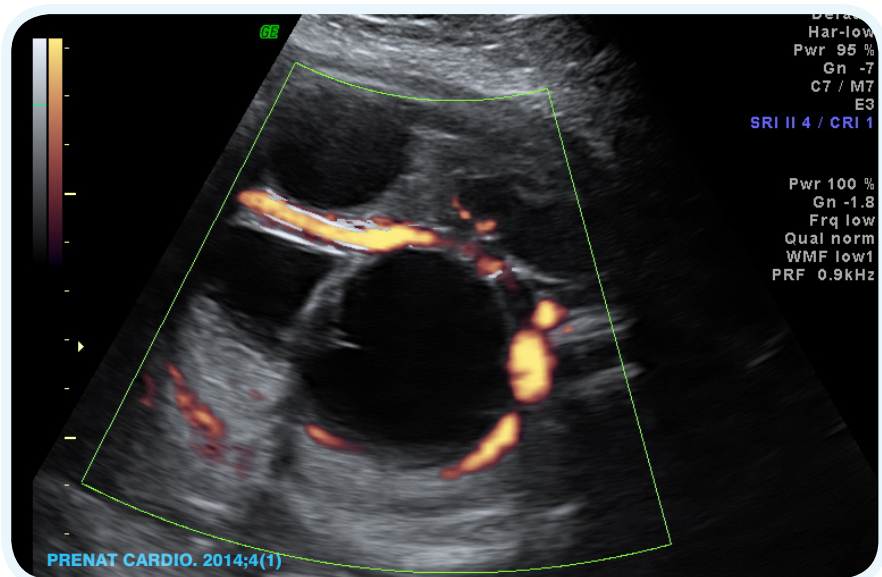


Photo 5. Abnormal fetal lower abdomen in case of cloaca: 3 big cysts and dilatation of the kidney's pelvis

which was not observed in the study group (only one fetus exhibited symptoms of heart defect).

We did not find in the literature or in our case material anomaly detection or diagnosis in first trimester of pregnancy, the youngest of our patients was 15 weeks, the average was 27,3 weeks of pregnancy. Most anomalies, both in our material, which, according to data from the literature, can be detected in the half of pregnancy but the diagnosis is usually made at late in the 3rd trimester<sup>7</sup>.

For the first time we draw attention to the role and importance of the fetal echocardiography with suspected Cloacal Malformation and not just the possibility of the coexistence of heart defects, which significantly worsens

PRENAT CARDIO. 2014;4(1)

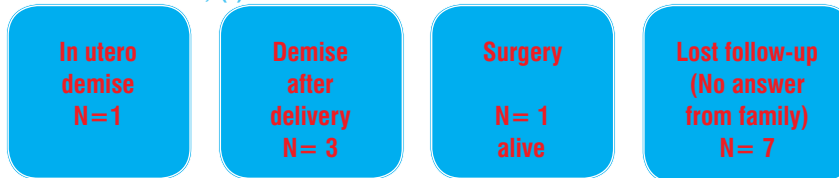


Table 4: Follow up of 12 fetuses with prenatal manifestation of cloaca

ovarian tumors, obstructive uropathy with a different mechanism, defects of the bladder, obstruction of the lower gastrointestinal tract or digestive tract duplication<sup>2,3,6,8,9</sup>

The two most common anatomic variants that newborns have are: single entrance to the vagina on the upper part of the urethra and rectum below the mouth and a double entrance to the vagina from the mouth of the rectum located in

the septum between the entrances to the vagina. For patients born, pediatric surgeons use a classification according to Holschneider<sup>5</sup>

Reconstructive surgery of defects is performed usually at the end of the first year of life.

**CONCLUSIONS:**

Prenatal diagnosis of cloacal defects is difficult at screening, as evidenced by the fact that neither one of the analyzed cases has ever been suspected diagnosis of Cloacal Malformation in obstetric screening.

Proper prenatal ultrasound diagnosis of cloacal defects is possible in a detailed study of the referral center and the main symptoms are: pelvic cyst symptoms and signs of obstructive uropathies and symptoms of compression to the final section of the digestive tract.

In 50% of fetuses with congenital Cloacal Malformation we've found the presence of functional changes in echocardiographic examination, what suggests overload of the circulatory system (preload or afterload) in this complex pelvic pathology.

Tab. 5. Pediatric Surgery Classification of Cloacal Malformation<sup>5</sup>

UGS – Urogenital sinus; PC pubococcygeal line

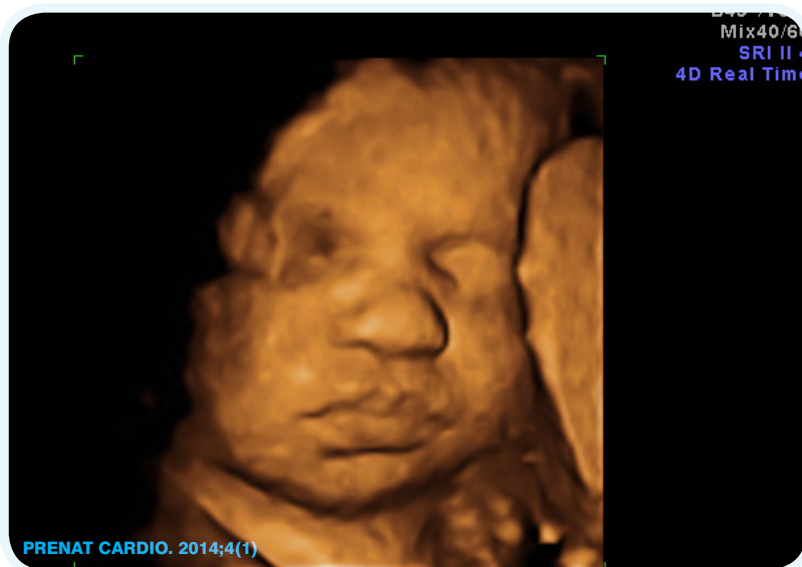

Photo 6. 3D presentation of the fetal face (no dysmorphic features) with cloaca (46XY)

the prognosis. The chances of surviving childbirth and the neonatal period have fetuses with normal cardiac anatomy<sup>9</sup>

In our study we draw attention to the prevalence of functional changes (in 50%) recorded by echocardiography. Probably the pathologic pelvic structures in the fetus causes in these cases overload of the cardiovascular system, increase preload or afterload. It should also take into account the possibility of coexistence in these fetal defects manifested functional changes in the cardiovascular system.

The symptoms of hydrocolpos in the fetus seems to be characteristic, but the differential diagnosis should be taken into account: atresia of the hymen, Urogenital Sinus, cystic

**References:**

1. Bianchi D. W., D'Alton M. E. *Persistent Cloaca, Fetology, Diagnosis and Management of the Fetal Patient, second edition, s. 585-589, ISBN 978-0-07-144201-5, McGraw-Hill Medical, New York 201*
2. Bischoff A, Levitt MA, Lim FY, Guimarães C, Peña A. *Prenatal diagnosis of cloacal malformations. Pediatr Surg Int. 2010 Nov;26(11):1071-5. doi: 10.1007/s00383-010-2685-3.*
3. Levitt MA, Peña A. *Cloacal malformations: lessons learned from 490 cases. Semin Pediatr Surg. 2010 May;19(2):128-38. doi: 10.1053/j.sempedsurg.2009.11.012..*

<b>Typ I / Type I</b>	<i>Anteposition of anus with ultra short urogenital sinus and normal female genitalia</i>
<b>Typ II / Type II</b>	<i>Short urogenital sinus &lt; 3 cm (confluence below pubococcygeal line)</i>
<b>Typ III / Type III</b>	<i>Long urogenital sinus &gt; 3 cm (confluence at or above pubococcygeal line)</i>
<b>Typ IV / Type IV</b>	<i>Vagina and /or rectum into bladder cavity</i>
<b>Rare types of cloaca</b>	<i>Posterior cloaca in boys, Cloacal extrophy</i>

Table 5: Classification of cloaca from pediatric surgery point of view

4. Bischoff A, Calvo-Garcia M. A., Baregamian N., Prenatal counseling for cloaca and cloacal exstrophy—challenges faced by pediatric surgeons *Pediatr Surg Int.* 2012 August; 28(8): 781–788. Published online 2012 August 10. doi: 10.1007/s00383-012-3133-3

5. Holschneider A. M., Scharbatke H. *Persistent Cloaca – Clinical Aspects, Anorectal Malformations in Children, Embryology, Diagnosis, Surgical Treatment, Follow-up* ISBN-10 3-540-31750-3 Springer Berlin Heidelberg New York 2006

6. Stodki Maciej, Respondek-Liberska Maria, Piaseczna-Piotrowska Anna. [Prenatal diagnosis of developmental disorders of lower urinary tract, vagina and rectum in the fetus]. *Prenat Cardio.* 2011 Dec;1(2):18-21. [Polish]

7. Baka-Ostrowska M. Comments to: Stodki Maciej, Respondek-Liberska Maria, Piaseczna-Piotrowska Anna. [Prenatal diagnosis of developmental disorders of lower urinary tract, vagina and rectum in the fetus]. *Prenat Cardio.* 2011 Dec;1(2):18-21. [Polish]

8. Mori M, Matsubara K, Abe E Prenatal diagnosis of persistent cloaca associated with VATER (vertebral defects, anal atresia, tracheo-esophageal fistula, and renal dysplasia). *Tohoku J Exp Med.* 2007 Dec;213(4):291-5.

9. Respondek-Liberska M., Krason M., Karczmarek P *Fetal hydrometrocolpos: not only diagnostic but also therapeutic dilemmas* *Ultrasound in Obstetrics & Gynecology* 1998, 11, 2, 155-156

**Conflict of interest: The authors declare no conflict of interest**  
**Author does not report any financial or personal links with other persons or organizations, which might affect negatively the content**  
**of this publication and/or claim authorship rights to this publication**

● **Commentary**

## PERSISTENT CLOACA - A CHALLENGE FOR AN EXPERIENCED SONOGRAPHER - COMMENTARY



**Autor:**  
 Marc A. Levitt, M.D.

*Cincinnati Children's Hospital, 3333 Burnet Avenue, ML 2023, USA*

This important contribution about the prenatal diagnosis of anorectal malformations further contributes to the literature in this emerging field. Evaluators of the fetus are becoming more savvy with the prenatal diagnosis of anorectal malformations – particularly noting the connection between ARMs and associated malformations such as renal anomalies, limb problems, and pelvic masses which could represent a hydrocolpos. In this review, prenatal

diagnosis of heart defects helped influence care of the newborn. With the assistance of such studies, the pediatric caregiver can continue to improve their role in helping the child born with these common congenital problems.